

Featured Movie: Celiac Artery involvement by Pancreas cancer

John C. Deutsch, MD

Gastroenterology
SMDC Health Sciences Center

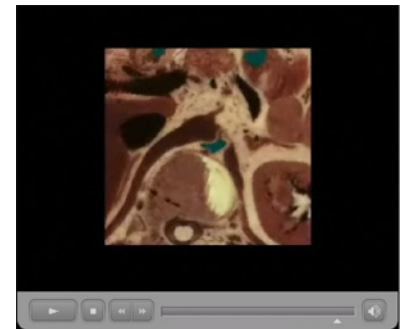
In the last edition of VHJOE, the featured movie showed the anatomic basis for T4 pancreas cancer involving the superior mesenteric artery¹. As noted in that article, vascular anatomy is important when staging a pancreatic tumor. According to the AJCC Cancer Staging Handbook², a T4 lesion, which is an unresectable presentation, occurs when the celiac or superior mesenteric arteries are involved by the cancer.

This edition shows the anatomy of T4 pancreas cancer involving the celiac artery. Whereas the superior mesenteric artery involvement is often best identified by EUS from the duodenum, the celiac artery is best evaluated from the stomach.

Visible Human anatomy and two examples of T4 pancreas cancer involving the celiac artery are shown.

References:

1. Deutsch, J. *T4 Pancreas Cancer*. <http://www.vhjoe.org/Volume8Issue3/8-3-8.htm>.
2. AJCC Cancer Staging Handbook, 6th Edition Greene, FL, Page, DL, Fleming, ID, Fritz, AG, Balch, CM, Haller, DG and Morrow, M, editors. **Springer Verlag 2002, New York, NY.**



Video Clip 1: Visible Human anatomy and two examples of T4 pancreas cancer involving the celiac artery.